

**LONG-TERM STABILITY OF  
ARCUATE INCISIONS CREATED  
WITH A NOVEL, DUAL PULSE  
FEMTOSECOND LASER SYSTEM  
FOR ASTIGMATISM MANAGEMENT**

**Presented by: Denise M. Visco, MD, MBA**

# INTRODUCTION

- As many as 63% of cataract patients have low levels of astigmatism (between 0.25 - 1.25 D).
- Even low levels of preexisting corneal astigmatism have been found to affect the accuracy of refractive outcomes achieved postoperatively.
- Arcuate keratotomy (AK) is an effective and low-cost method of reducing astigmatism at the time of cataract surgery and achieving optimal outcomes postoperatively.
- While AKs created with the femtosecond laser have been found to be of precise depth, arc length, and location, allowing good predictability of corneal astigmatism correction, astigmatic outcomes have been found to regress over time.
  - This has been attributed to wound gaping and the formation of an epithelial plug.

# INTRODUCTION

- ALLY femtosecond laser (LENSAR) is a dual-pulse laser with two separate laser profiles - one for corneal incisions (320 fs pulse-width) like AI, clear corneal incisions, and the other (1500 fs pulse-width) for capsulotomy and nuclear fragmentation.
- The LENSAR femtosecond laser creates arcuate incisions perpendicular to the coronal plane, which reduces the risk of astigmatism regression.
- The 6 fixed Scheimpflug cameras in the ALLY dual-pulse laser allow faster imaging, making femto procedure 2-4 times faster than the previous generation laser.
- The iris registration maneuver allows for precise alignment of AK incisions created with ALLY femtosecond laser on the intended meridian, thereby significantly improving the predictability.

## PURPOSE

- To assess the long-term stability of astigmatism correction with arcuate incisions created using a novel, dual-pulse femtosecond laser.

# METHODS

---

**Study design:** Retrospective chart review.

---

**Study procedure:** Case records of patients (N=22) who had undergone ALLY femtosecond laser-assisted arcuate keratotomy for astigmatism correction were reviewed. Postoperative data at 4 to 6 weeks and 24 to 36 months were retrieved from the case records and analyzed.

---

**Outcome  
measures:**

Comparison of keratometric astigmatism along the original steep and orthogonal meridians; percentage of cases with  $\leq 0.25D$ ,  $\leq 0.50D$ , and  $\leq 1.00D$  of residual astigmatic correction.

---

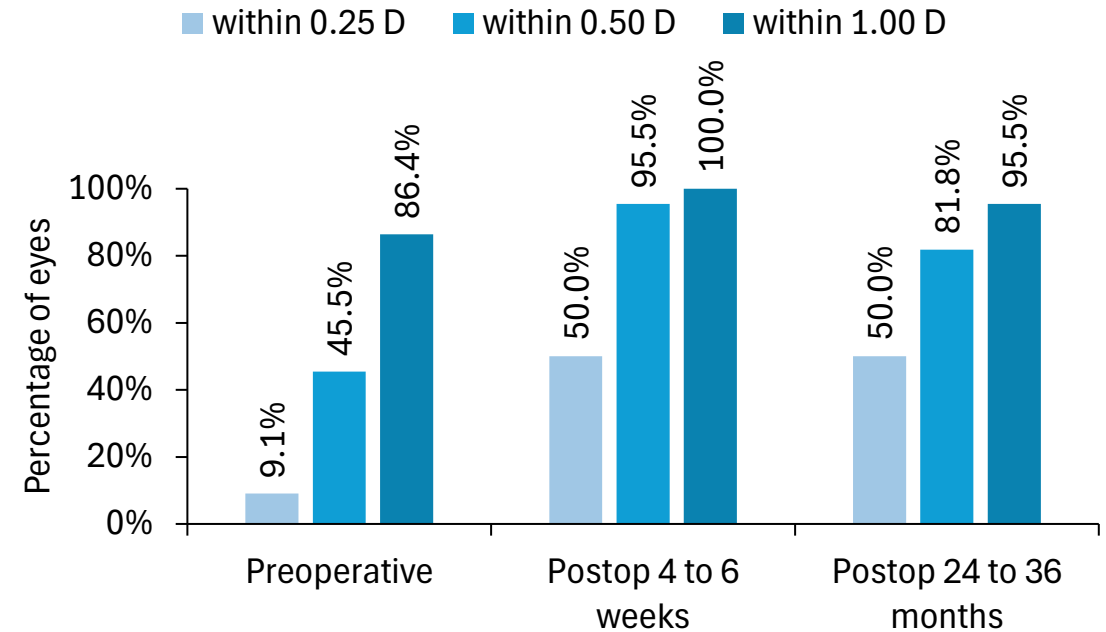
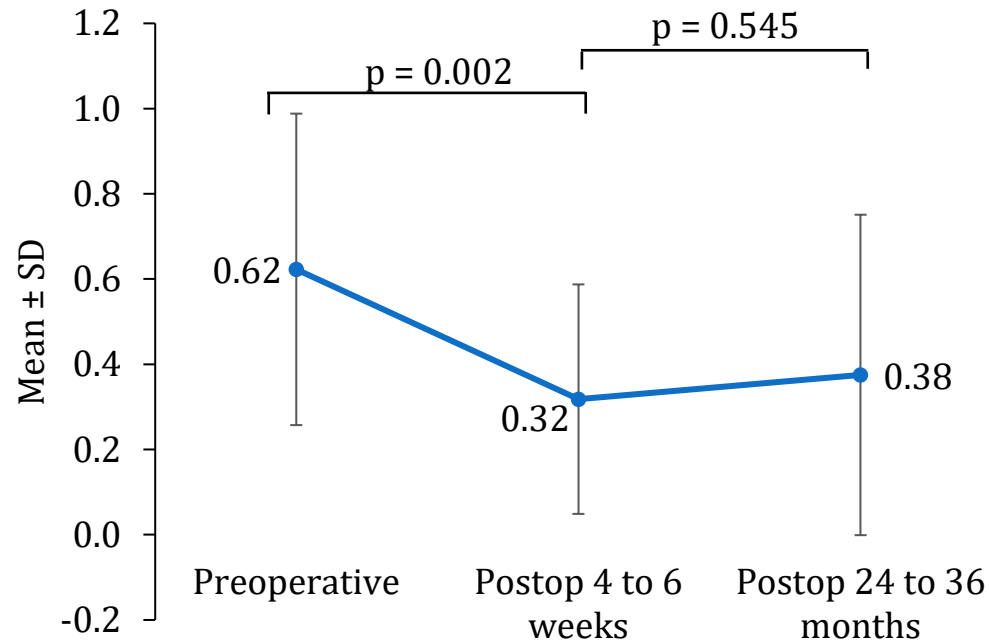
Vector analysis and surgically induced astigmatism, difference vector, correction index, angle of error.

---

Changes in UCVA at varying time intervals up to 36 months were evaluated.

---

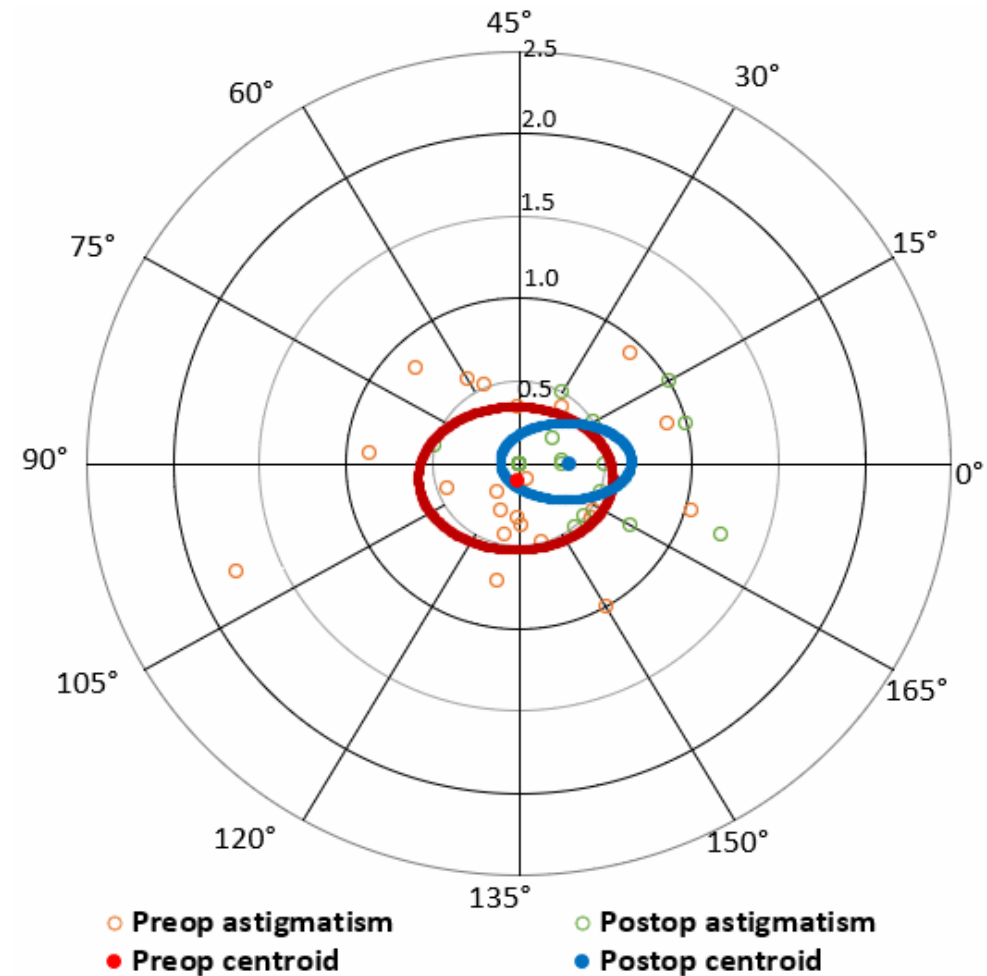
# RESULTS



- There was a statistically significant reduction in preoperative astigmatism to postoperative 4 to 6 weeks, which was maintained up to postoperative 24 to 36 months.

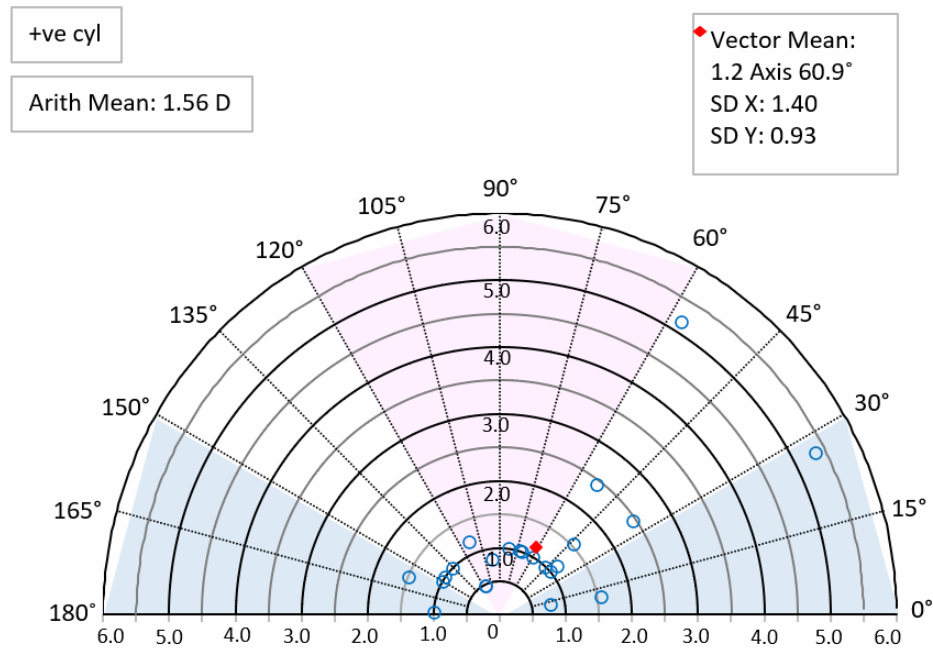
# RESULTS: DOUBLE ANGLE VECTOR PLOT

- Vector analysis revealed a postoperative reduction in vectoral standard deviation, as represented by the postoperative ellipse.

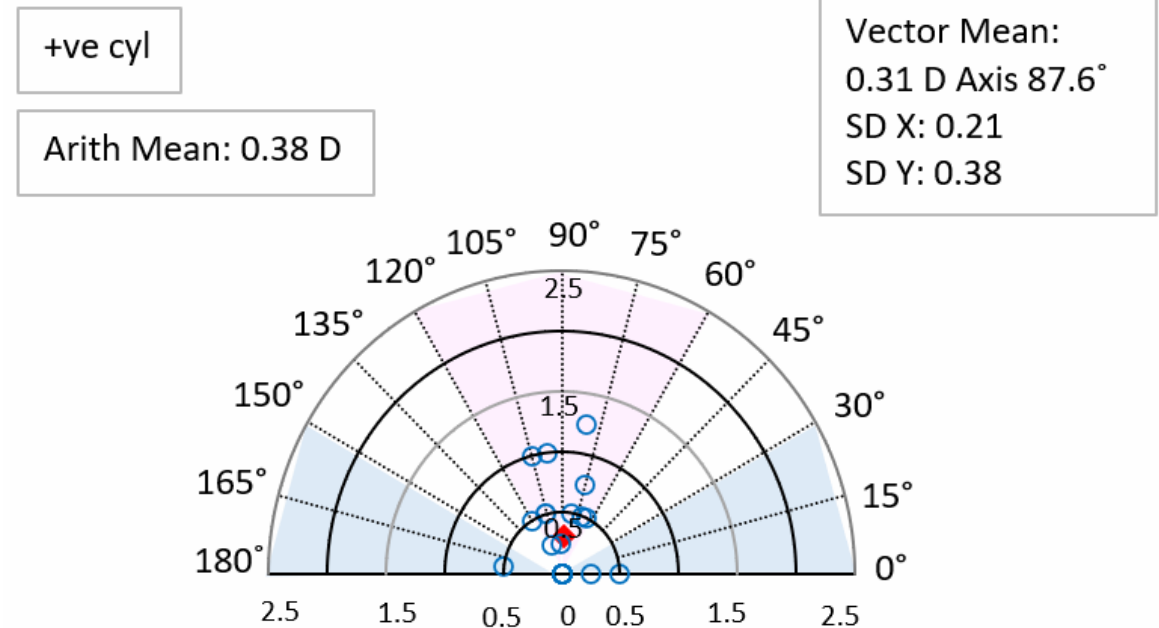


# RESULTS

## Correction Index



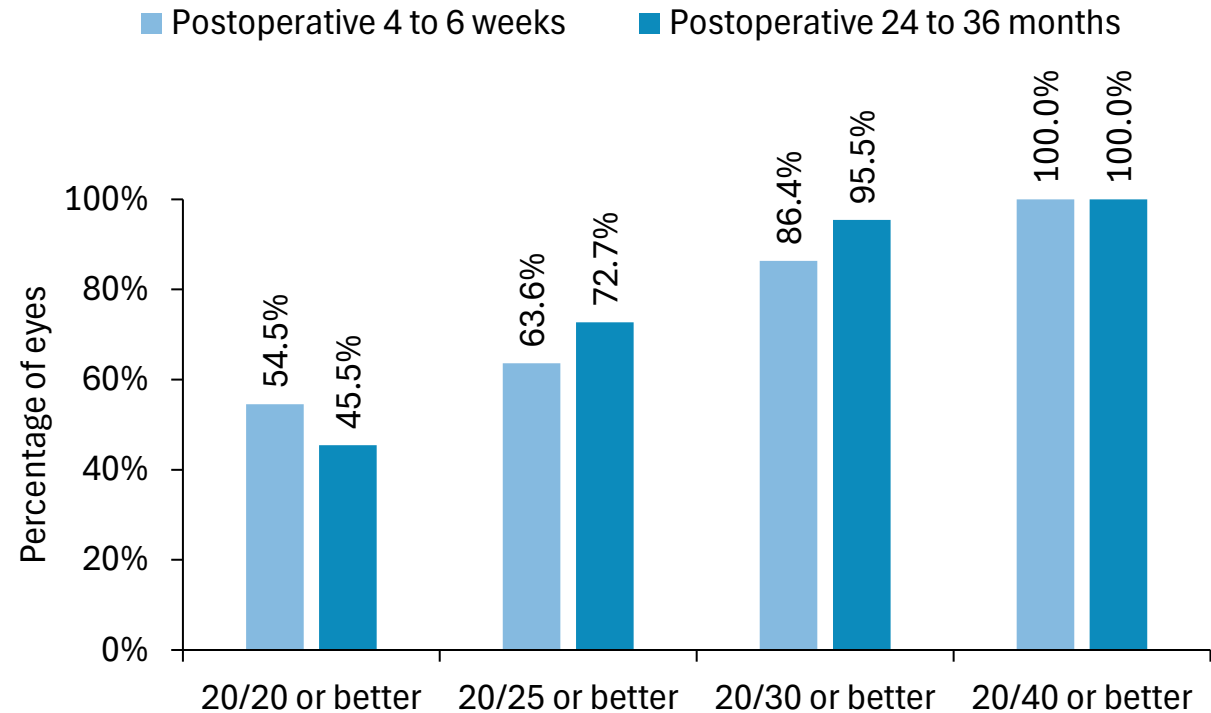
## Difference Vector



- The mean correction index of 1.2 indicates slight overcorrection; however, the difference vector was small.

# RESULTS: UDVA

- Mean UDVA was maintained from postoperative 4 to 6 weeks ( $0.09 \pm 0.11$  logMAR) to 24 to 36 months ( $0.08 \pm 0.09$  logMAR).
- At postoperative 24 to 36 months, 95.5% of the eyes had a postoperative UDVA of 20/30 or better.



# CONCLUSION

- This study demonstrates that femtosecond laser–assisted beveled arcuate keratotomies performed during cataract surgery were effective in reducing astigmatism.
- The 24 to 36 months outcomes support long-term refractive stability of LENSAR femtosecond laser–assisted beveled arcuate keratotomies.

**THANK YOU**