

# Validation of Iris Registration-guided Femtosecond Laser Capsular Marks to guide Toric IOL Alignment with Intraoperative Aberrometry

Presented by: P DEE STEPHENSON, MD, FACS

# Disclosure

# Introduction

- Accurate alignment of the toric IOL is important when correcting pre-existing corneal astigmatism during cataract surgery with toric IOLs.
- Image-guided systems with digital overlay provide more accurate alignment of toric IOLs compared to conventional manual ink marks.<sup>1</sup>
- Intraoperative aberrometry can also guide the intraoperative alignment of toric IOL.<sup>2</sup>
- A novel approach to toric IOL alignment involves the construction of a pair of small pointers or marks on the capsular rim 180° opposite to one another during a standard laser capsulotomy procedure (IntelliAxis-L refractive capsulorhexis; LENSAR). These CMs:
  - provide a visual guide to align the toric IOL intraoperatively.
  - allow postoperative assessment of the rotational stability of the IOL.

# Purpose

- To validate toric IOL alignment by iris registration-guided femtosecond laser-assisted capsular marks with pseudophakic intraoperative aberrometry measurements.

# Methods

## Study design:

- Retrospective study.

## Study population:

- 284 eyes that underwent FLACS and toric IOL implantation.

## Study procedure:

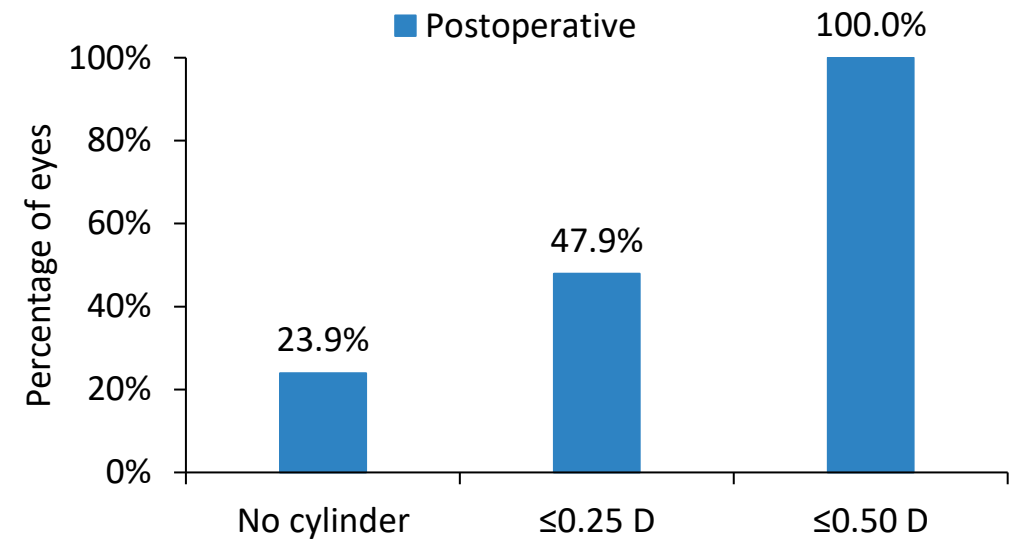
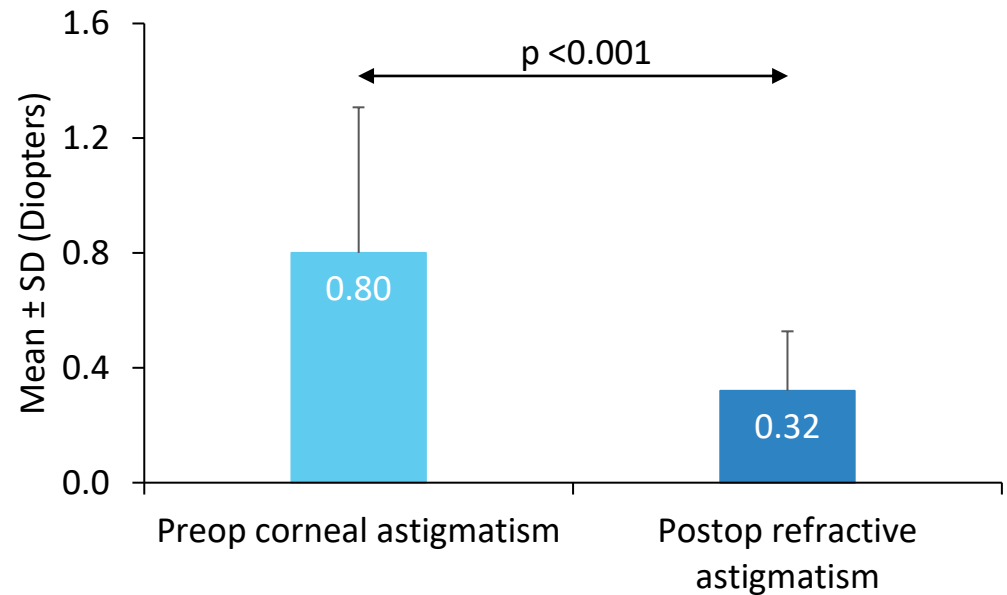
- Toric IOL alignment performed using iris registration-guided CMs placed on the capsular rim (LENSAR IntelliAxis-L Refractive Capsulorhexis) and confirmed with intraoperative aberrometry (ORA, Alcon).

## Outcome measures:

- Mean preop corneal and postop refractive astigmatism; postoperative mean UDVA and spherical equivalent.

# Results

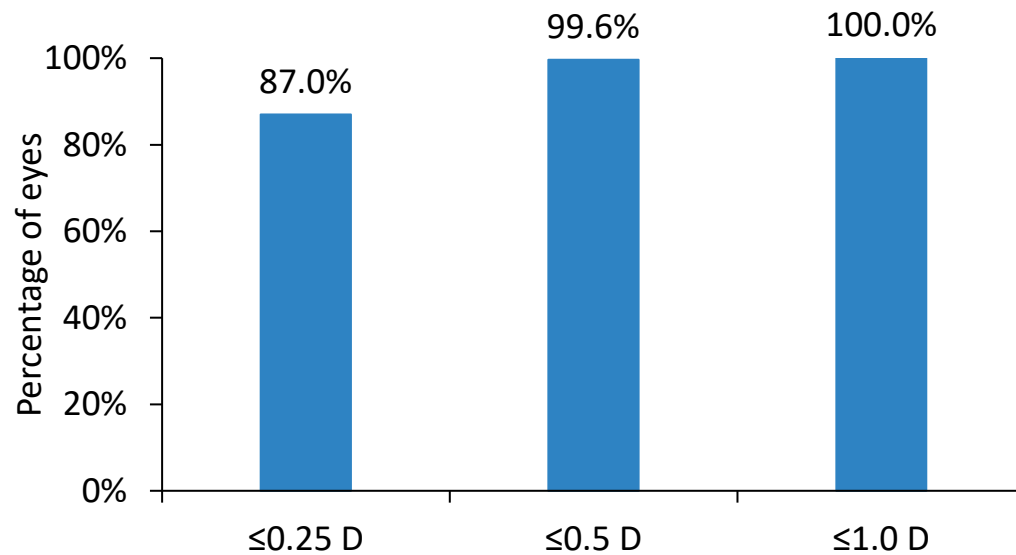
## Preop corneal vs postop refractive astigmatism



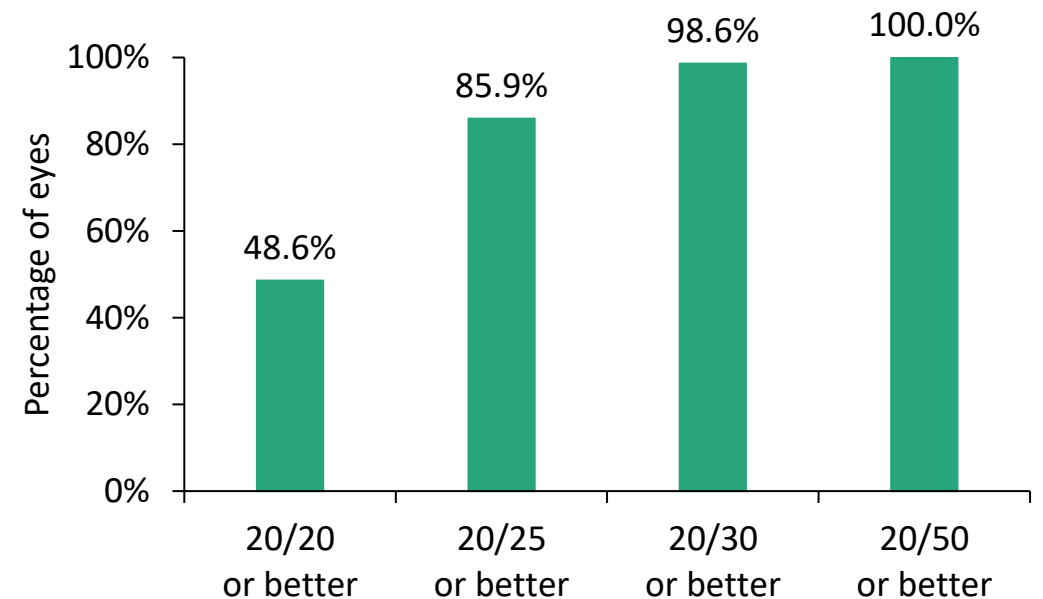
Implantation of toric IOLs led to a statistically significant reduction in astigmatism, with all eyes achieving residual astigmatism within 0.5 D postoperatively.

# Results

**Postoperative MRSE**  
Mean:  $-0.02 \pm 0.23$  D



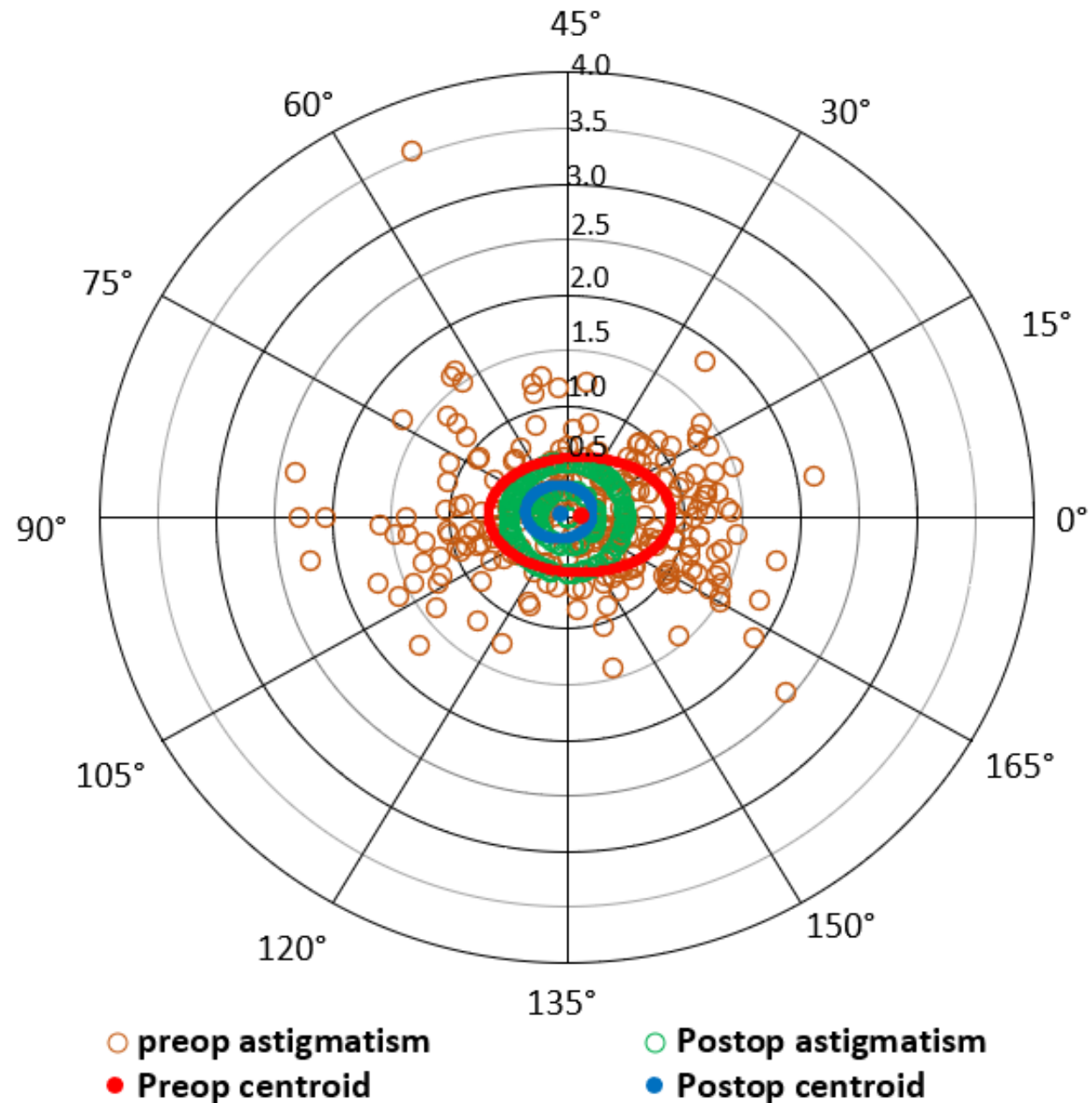
**Postoperative UDVA**  
Mean:  $0.06 \pm 0.07$  logMAR



There was a significant reduction in postoperative MRSE and 99% of eyes showed UDVA 20/30 or better postoperatively.

# Results

- Centroid of postop astigmatism was closer to 0.0 D and had a smaller vectoral standard deviation (represented by ellipse).



# Discussion and Conclusion

- Refractive capsulorhexis (LENSAR IntelliAxis-L) combines the advantages of a femtosecond laser capsulotomy with a one-step visual guide for intraoperative toric IOL alignment as well as postoperative assessment of rotational stability.
- With IntelliAxis capsular marks, concern regarding parallax is practically eliminated because the plane of the anterior capsule is very close to the plane of the IOL.
- In the present study, the alignment of toric IOL using IntelliAxis-L guided capsular marks was in agreement with the pseudophakic Intraoperative aberrometry (IA) measurement.
- Femtosecond laser-assisted cataract surgery and implantation of toric IOL guided by iris registration-guided capsular marks were effective in reducing pre-existing corneal astigmatism in cataract patients yielding excellent visual and refractive outcomes.
  - Postoperatively, all eyes had residual astigmatic error within 0.5 D.

**THANK YOU**