



ALLIANCE VISION
INSTITUTE

SHOULD I OR SHOULDN'T I?

Taylor Strange, DO

Fort Worth, TX

DISCLOSURES

- ▶ Johnson and Johnson
- ▶ LENSAR



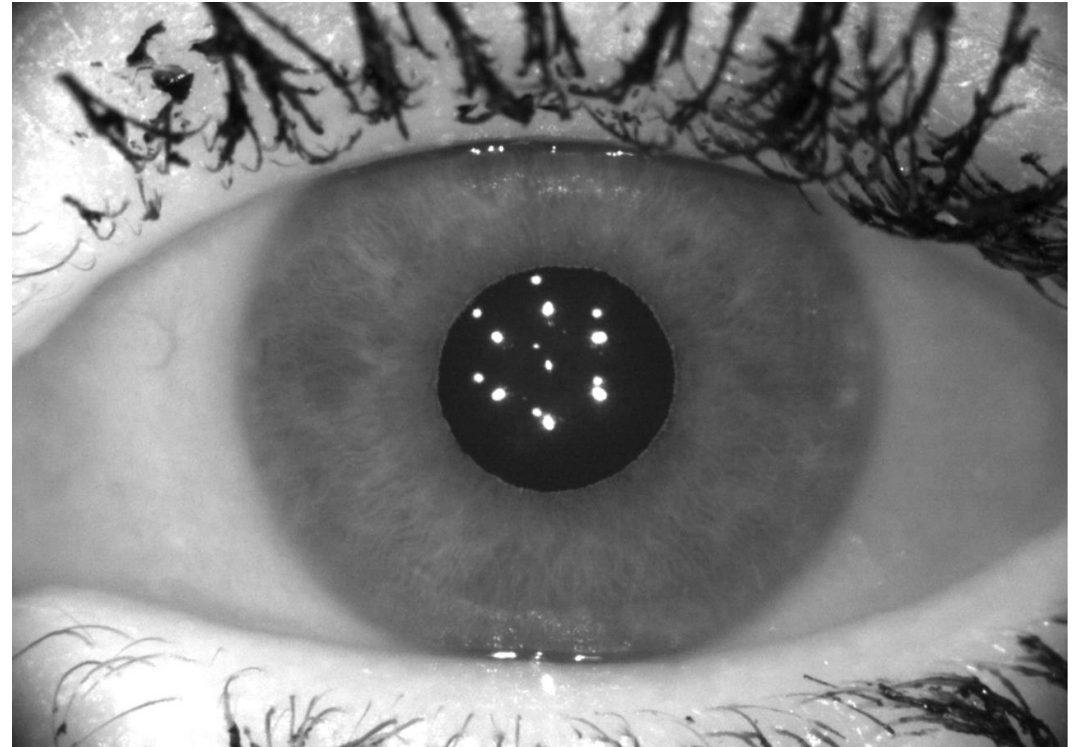
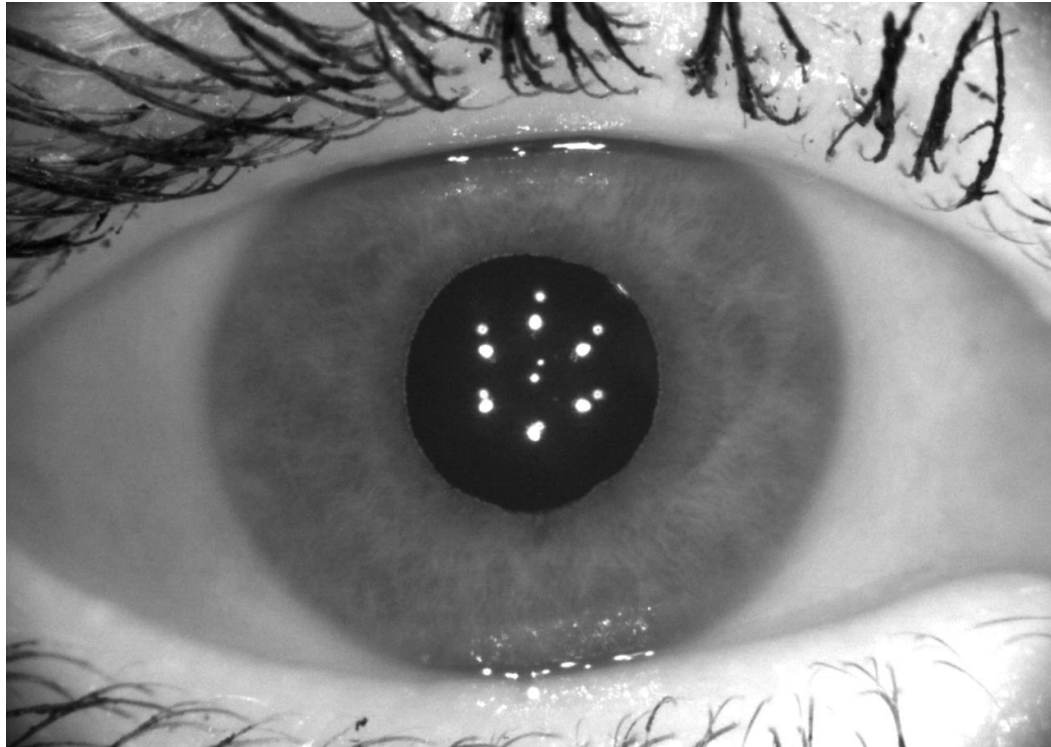
ALLIANCE VISION
INSTITUTE

PATIENT OVERVIEW

- 52 y/o female with 2+ NS/cortical cataracts OU
- s/p Visian ICLs 2016 OU
- Patent PIs OU, Normal IOPs
- OD: -1.25 -0.75 022
- OS: -1.00 -0.75 007



THE QUESTION



Do I remove the ICLs and perform manual LRIs or perform Robotic LCS over the ICLs?

SURGICAL PLAN

ALLY Robotic Laser Cataract Surgery with Odyssey IOLs

PQ Unknown - Incomplete Patient Questionnaire


Left Eye Prior Refractive Surgery: No Keratoconus: No Monovision History: No

Edit Status Approved - NEW DATA 2nd eye

Procedure	Cataract extraction with IOL
Procedure Subtype	FLACS with corneal incisions
Surgeon	Taylor Strange
Surgery Date	01/23/2024
Refraction	-0.25 + 0.75 x 93° (20/20)
Anterior Keratometry	0.80 @ 79° (Pentacam)
Posterior Keratometry	
Net Astigmatism (D)	0.41 @ 78°
Target	Distance
Arcuate Incisions	None

Arcuates? Operate on-axis

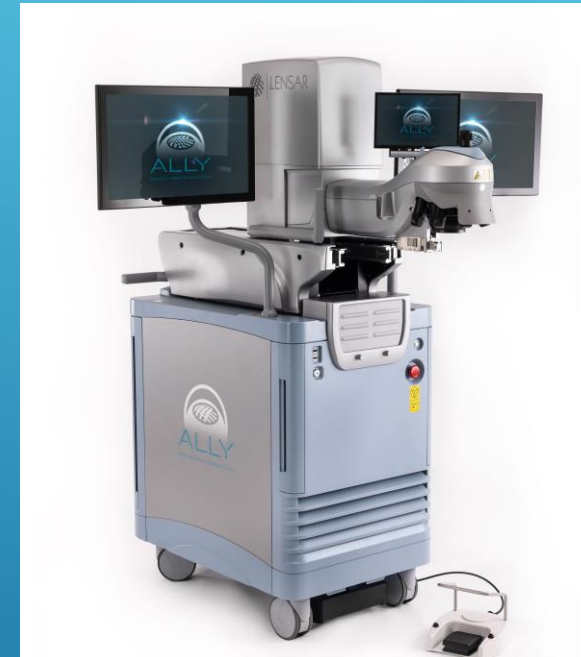No Alerts



Tecnis Odyssey DRN00V
+8.00 D


Predicted Final Refraction
-0.26 + 0.41 x 78° (SE -0.06)

Unapprove



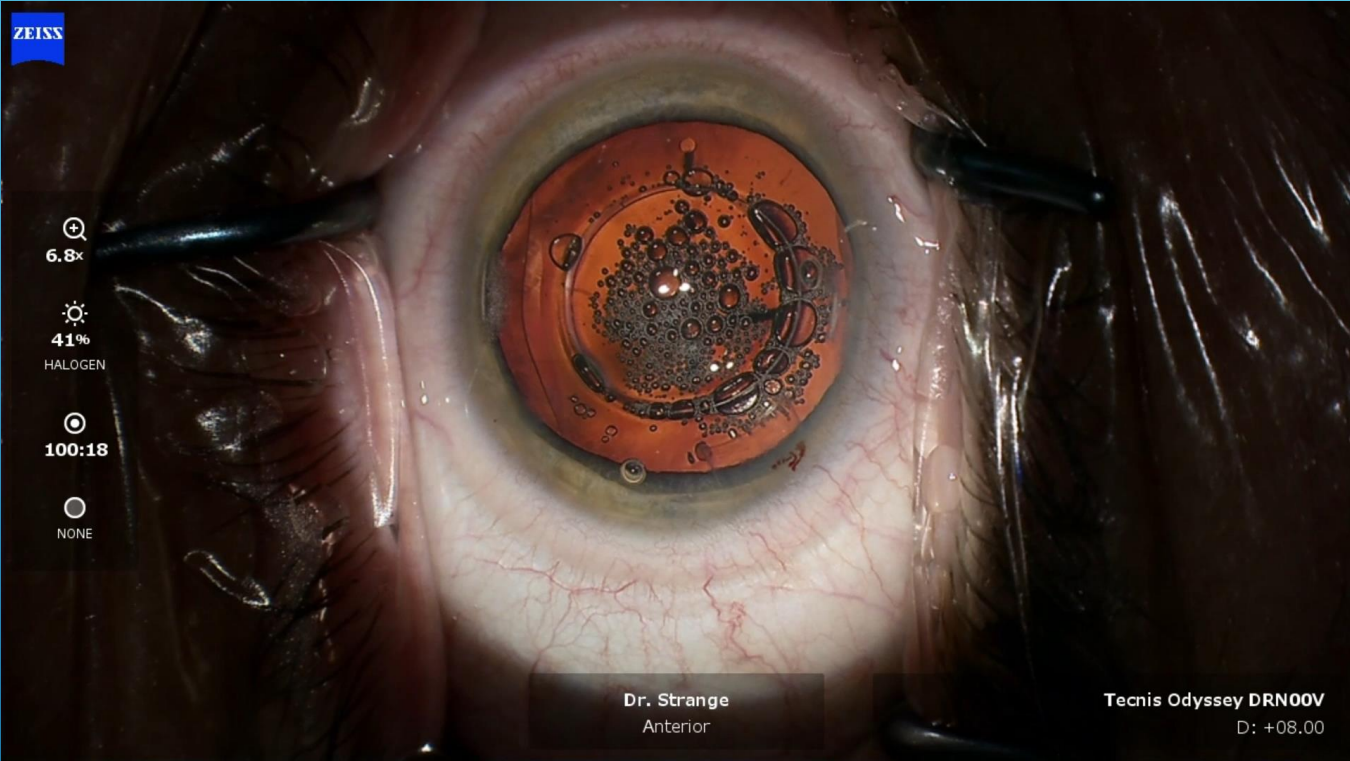
ALLIANCE VISION
INSTITUTE

ALLY PROCEDURE



ALLIANCE VISION
INSTITUTE

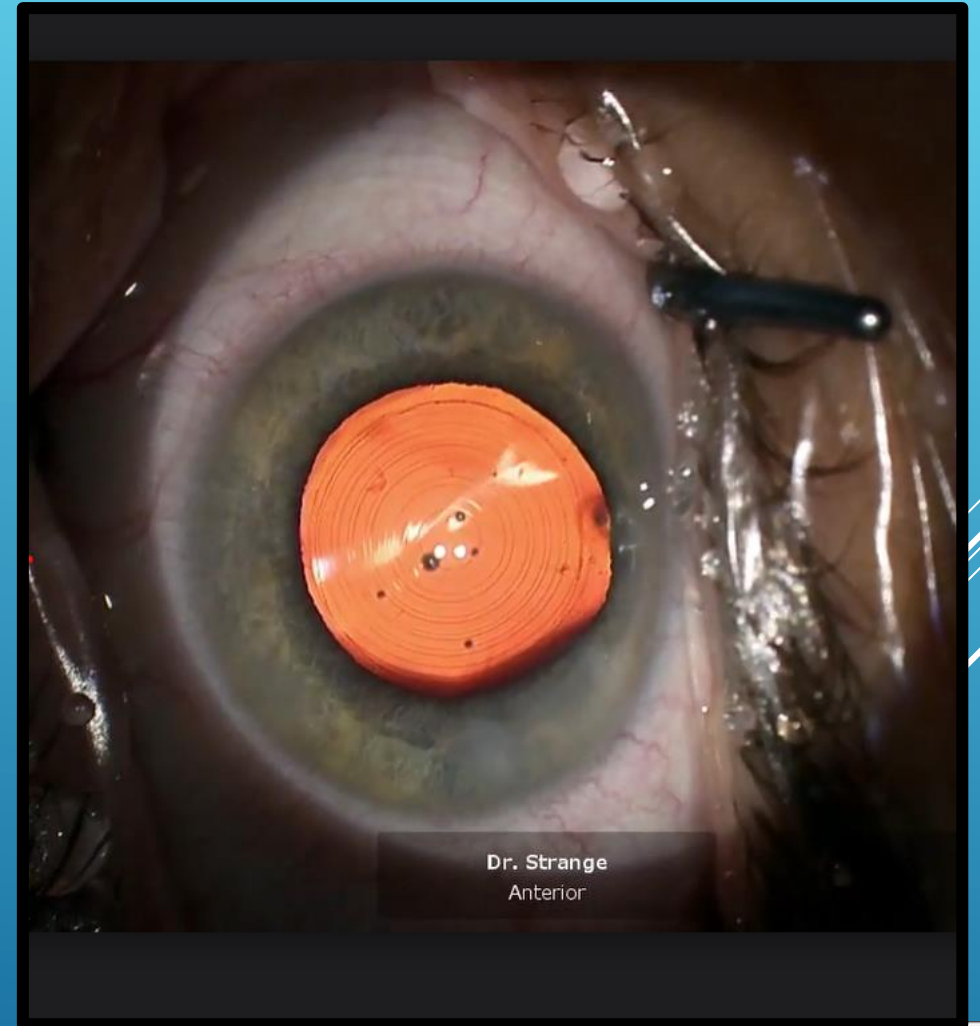
COMPLETION OF PROCEDURE



THE OUTCOME

Dsc 20/20 OU J1+

Happy outcome for patient and surgeon!



Dr. Strange
Anterior



ALLIANCE VISION
INSTITUTE



THANK YOU



ALLIANCE VISION
INSTITUTE